



mucoderm[®]

3D REGENERATIVE TISSUE GRAFT

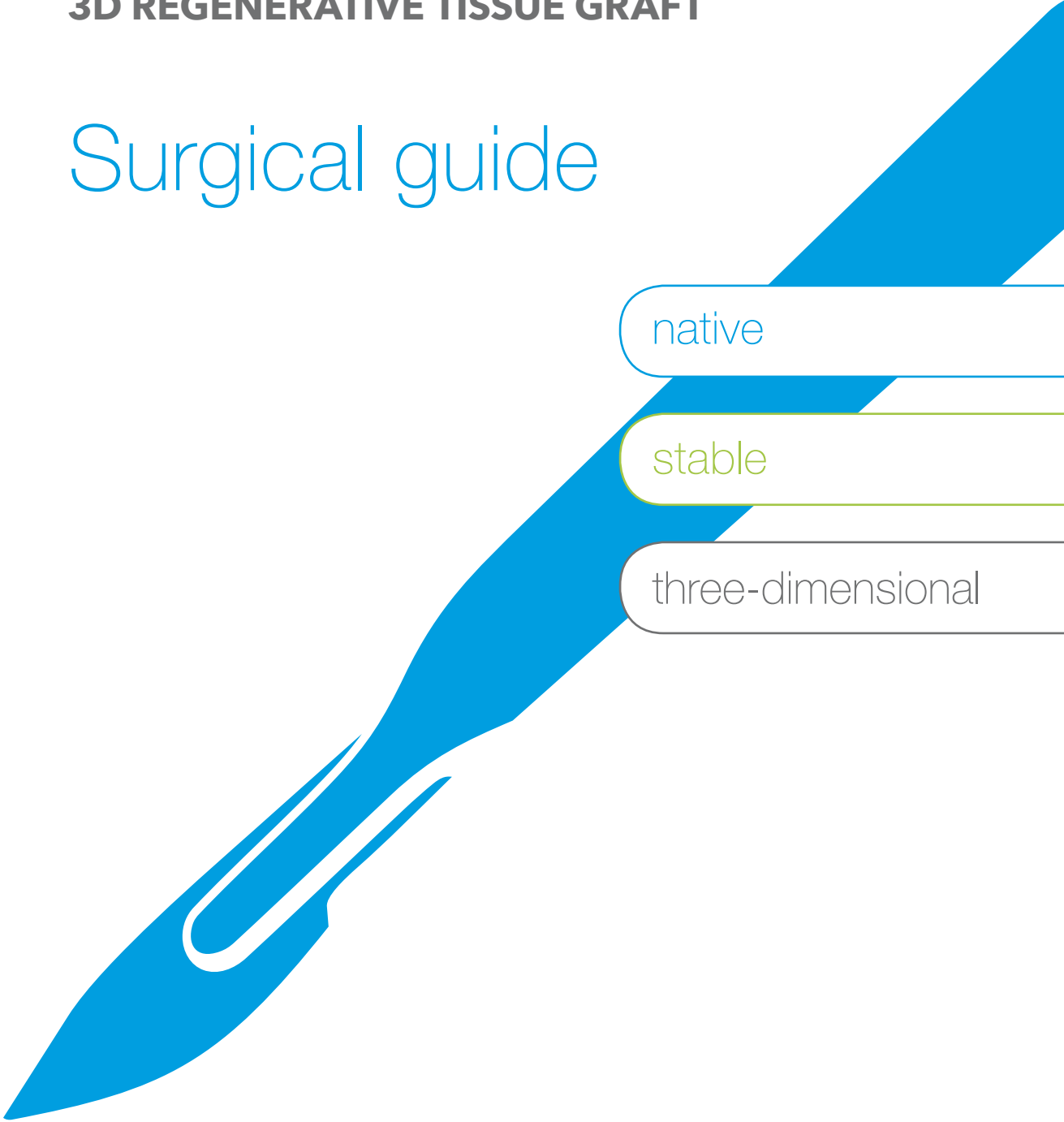
Surgical guide

soft tissue

native

stable

three-dimensional



About the surgical guide

This surgical guide was created with the support of internationally renowned clinical experts to assist you in achieving the best possible and predictable results with mucoderm® in the indications hereafter described.

On the following pages, you will find detailed information on the application of mucoderm®, with general handling tips and technical descriptions in order to handle specific clinical situations.

Each indication is described by a clinical case from an expert, demonstrating a recommended surgical procedure.

Why do we need soft tissue replacement grafts?

Today, modern techniques of plastic-aesthetic periodontal surgery ensure a predictable regeneration of soft tissue deficiencies in the majority of cases. The use of free mucosal transplants and subepithelial connective tissue grafts, both commonly harvested from the palate, is still considered the gold standard. However, the availability of connective tissue at the donor site is limited, particularly in patients with a thin gingival biotype or if multiple recessions should be treated^{1,2}. Furthermore, connective tissue harvesting can be associated with significant disadvantages such as an increase in surgery time and patient morbidity as well as a higher risk for post-operative complications^{3,4}.

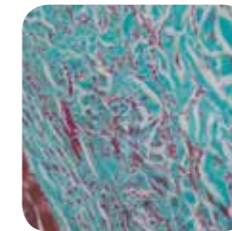
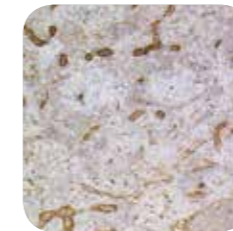
mucoderm® as an alternative to autologous soft tissue grafts

To overcome the disadvantages associated with tissue harvesting, allogenic and xenogenic collagen-based materials have been developed in recent years. These may serve as an alternative to autologous grafts. One of these materials is mucoderm®, an acellular collagen matrix, derived from porcine dermis that undergoes a multi-step purification process, which removes all antigenic components. This processing results in a three-dimensional stable matrix, which consists of collagen and elastin with a natural collagen structure that resembles the human connective tissue⁵. After implantation, this collagen network serves as a scaffold for the ingrowth of blood vessels and cells, thus supporting a fast revascularization and tissue integration⁶. The simultaneous degradation of the matrix and the collagen production of adhering fibroblasts lead to a complete substitution of mucoderm® by the newly formed host tissue⁷.

mucoderm® has a collagenous architecture beneficial for cell ingrowth


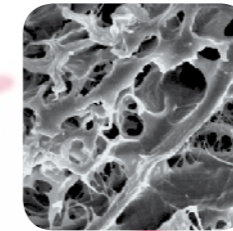
Surface and cross sectional SEM as well as synchrotron analysis of mucoderm® demonstrated a high interconnected porosity of the collagen matrix, making it an excellent scaffold for ingrowing cells and vessels^{6,8}. Attracted by the signals of activated migrating and proliferating fibroblasts, blood vessels from the surrounding tissue will grow into the matrix. At the same time, fibroblasts adhere and spread onto the matrix. While collagen is produced by the adhering cells, the matrix is gradually degraded and finally replaced by host tissue⁷.

Histological examination after subcutaneous implantation in mice showed extensive ingrowth of vessels (immuno staining, endothelial marker) after 21 days⁶.

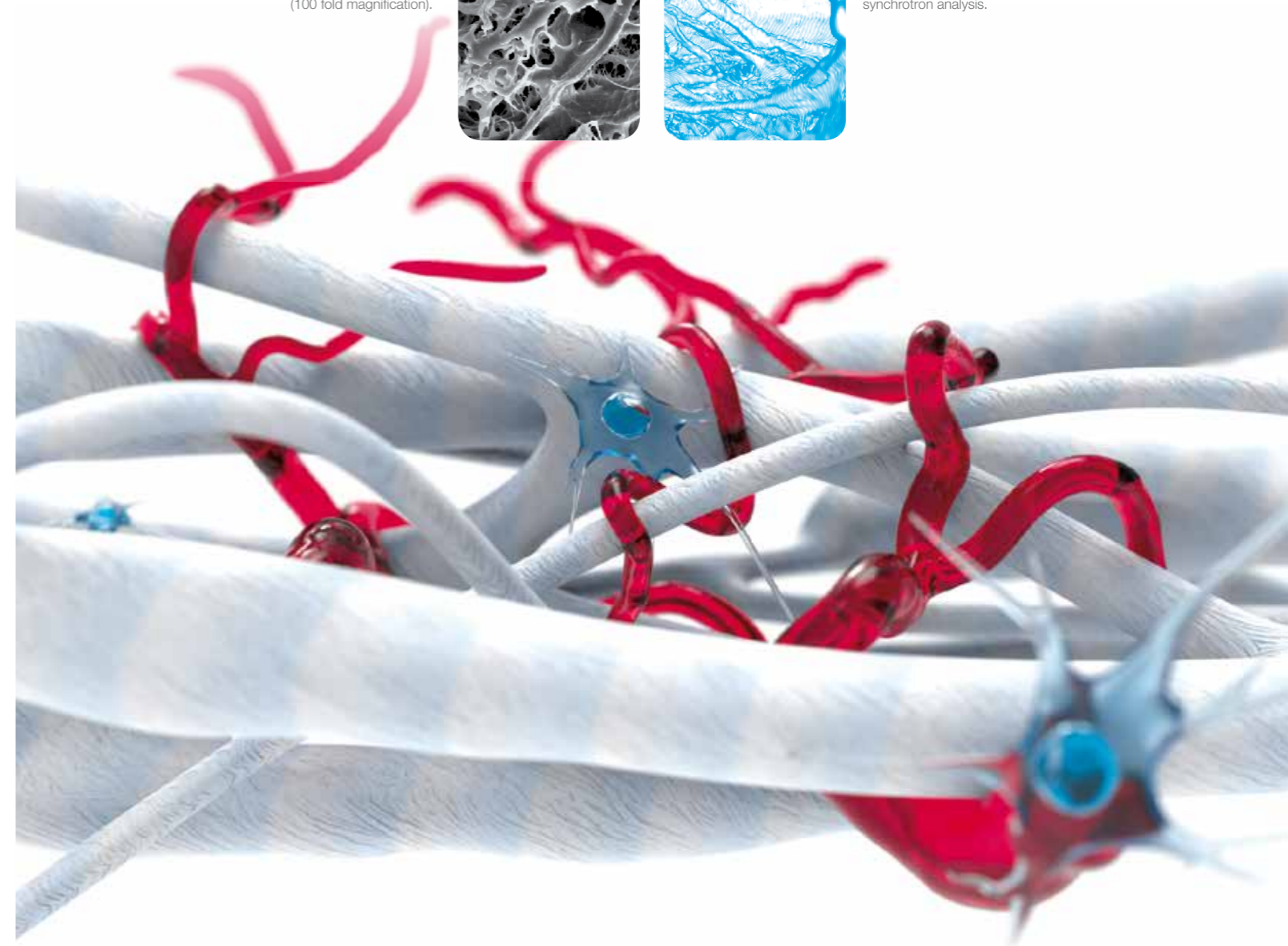


Two weeks after subcutaneous implantation in rats (Mason Goldner staining). Good integration with invasion of cells and vessels⁷.

SEM image of mucoderm® (100 fold magnification).



Fibre structure of mucoderm® shown by synchrotron analysis.



General guidelines for the use of mucoderm®

- For a successful clinical outcome with mucoderm® in the treatment of recessions, patients must be selected based on their Miller-class type (I-III) and their compliance with the post-surgical instructions.
- mucoderm® must not be used in patients with acute or chronic inflammation at the implantation site.
- The size of the graft should be adapted to the specific situation. Cutting can be performed with scissors or a blade, preferably in a rehydrated state, while maintaining sterility.
- mucoderm® should always be applied after hydration (in sterile saline, defect blood, or platelet concentrates). For further details, please see page 5.
- If the matrix is only very shortly rehydrated, rounding of the edges can help to prevent a perforation of the gingiva following flap closure.
- Since mucoderm® is a multilayer matrix, its sides are comparable, i.e. no attention needs to be paid to the orientation of the graft.
- For augmentation of attached gingiva (in course of a vestibuloplasty), it is recommended to adapt mucoderm® to the wound bed using moderate pressure. The time required depends on the extent of the bleeding.
- Following application, mucoderm® should always be stabilized to avoid micromovements and ensure undisturbed revitalization, e.g. ingrowth of vessels and cells.
When preparing a split flap, mucoderm® should be sutured to the intact periosteum to ensure close contact between the matrix and the periosteal wound bed. Single button or cross sutures may be used; the use of resorbable sutures is recommended.
- During open healing, the supply and revascularization of the matrix must be guaranteed, e.g. through close contact with the underlying periosteum. Always avoid exposure of mucoderm® when used in recession coverage or in combination with a bone grafting procedure.
- After surgery, it is necessary to avoid any mechanical trauma of the treated site. Patients should be instructed not to brush in the treated area for four weeks following the surgery. Plaque prevention can be achieved by rinsing with 0.12% chlorhexidine solution twice a day.
- Post-operatively, the patient should be recalled weekly for plaque control and healing evaluation.



Importance of revitalization and tissue integration

Since mucoderm® is an acellular matrix, it requires proper revitalization through blood vessels and cells, which grow in from the underlying or overlying soft tissue.

A complete flap reposition over the matrix is of utmost importance when the revascularization from underneath is not likely, e.g., when the mucoderm® is placed on:

- Denuded tooth root surfaces (recession coverage)
- Grafting materials (soft tissue thickening in combination with GBR)
- In direct bone contact (e.g thickening of periimplant tissue)

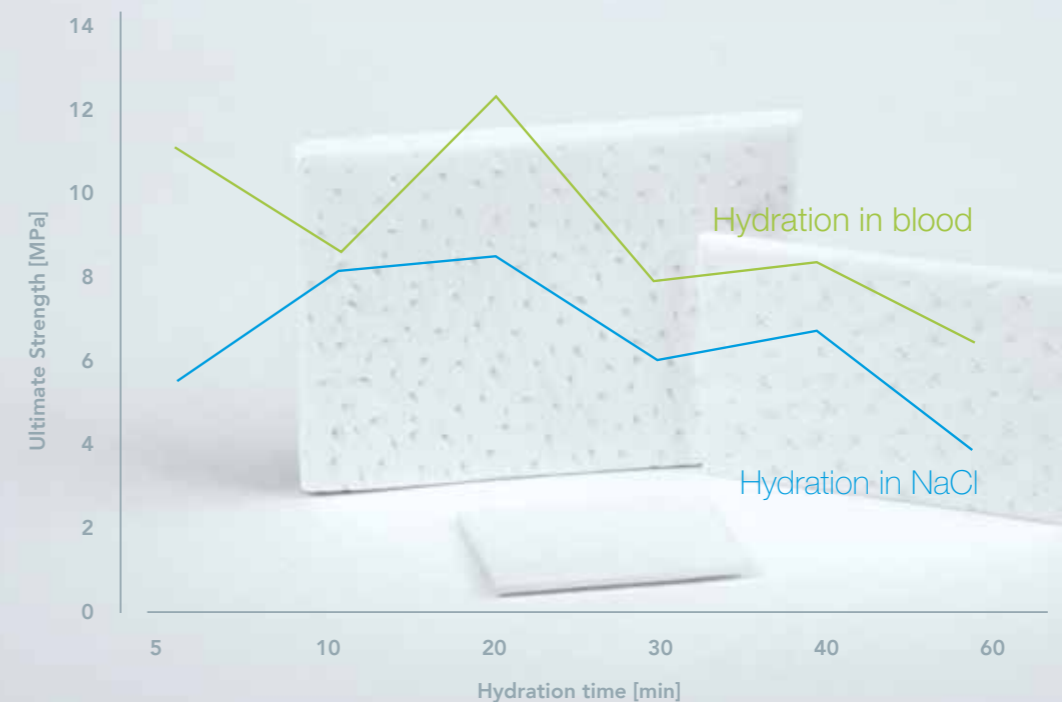
In which clinical situations is an open healing possible?

mucoderm® should only be left for open healing, if a revitalization from the surrounding or underlying wound bed is ensured. Open healing is feasible in the case of a vestibuloplasty, if mucoderm® is sutured to the periosteum. In this case mucoderm® should be closely fixed to the periosteum. This facilitates an increase in the width of the attached gingiva but not in the thickening of the tissue. Open healing is also possible if only minor parts of the matrix are exposed and revascularization is ensured by the surrounding margins of the flap or by the underlying periosteum. Please note that the degradation time depends on the extent of the exposure and will be faster due to bacterial decontamination and resorption.

Hydration of mucoderm®

The hydration protocol and its influence on the biomechanical properties of mucoderm® were analyzed in a study by Prof. Dr. Dr. Adrian Kasaj².

- mucoderm® demonstrated optimal mechanical properties after a rehydration time of 10 to max. 20 minutes
- Hydration in blood can improve the biomechanical properties of mucoderm®
- The optimal hydration time depends on the applied technique as well as individual preferences and is mentioned in each of the following cases



Indications for mucoderm®

| | |
|---|---|
| mucoderm® for the treatment of gingival recessions | p7 |
| Recession coverage with the modified coronally advanced flap technique Prof. Dr. Dr. Adrian Kasaj | p8-9 |
| Covering of multiple recessions with the modified coronally advanced tunnel (MCAT) technique PD Dr. Raluca Cosgarea | p10 |
| Multiple recession root coverage with the modified coronally advanced tunnel (MCAT) technique PD Dr. Raluca Cosgarea and Prof. Dr. Dr. Anton Sculean | p11 |
| Augmentation of attached gingiva with mucoderm® | |
| Full arch reconstruction of insufficient vestibular depth and lack of keratinized tissues Dr. Bálint Molnár and Prof. Dr. Péter Windisch | p12 |
| mucoderm® for the thickening of periimplant soft tissue | |
| Mucosal thickening around bone level implants Dr. Algirdas Puisys | p13 |
| This surgical guide provides clinically based information for the correct handling and application of mucoderm®. Nevertheless, the proper handling according to the instruction for use as well as the choice of the application of mucoderm® in each specific clinical situation lie within the responsibility of the clinician. | botiss provides continuing education on its products to ensure long-term success and predictable aesthetic outcome. Please refer to your local representative for courses and trainings on mucoderm®. |

mucoderm® for the treatment of gingival recessions

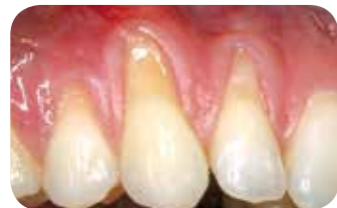Guidelines for the application of mucoderm® in gingival recession coverage

- mucoderm® may be used to treat Miller-class I and II recessions (single and multiple adjacent), as a successful alternative to autologous connective tissue transplants^{10,11}.
- Although the application of mucoderm® in the treatment of Miller-class III recessions has been reported with a positive outcome, results are typically less predictable compared to those obtained in Miller-class I and II recessions¹⁰. In principle, the predictability and success rate for the treatment of defects in the maxilla is higher as compared to that of mandibular defects.
- mucoderm® can be used in combination with all mucogingival surgical techniques, including coronally advanced flap and tunnel techniques. Notably, the classical coronally advanced flap or the modified coronally advanced flap ensure a good view on the prepared donor bed and facilitate the coronal repositioning of the flap over the matrix.
- For recession coverage, mucoderm® must always be completely covered by the flap in order to ensure revitalization of the graft. Post-operative exposure of mucoderm® may cause premature resorption of the matrix and must therefore be avoided.
- Advanced flaps need to be sufficiently mobilized to avoid tension of the soft tissue. When applying mucoderm® for recession coverage, special attention must be paid to achieve sufficient flap mobilization and tension-free closure.
- A proper vascular supply from the prepared flap¹² is critical to achieve an appropriate revascularization of the mucoderm® matrix. In particular, split flaps must be sufficiently thick to ensure revitalization of the matrix and the remodeling into the patient's own connective tissue.
- If it is not possible to mobilize the flap appropriately and a submerged healing of mucoderm® cannot be ensured, the application of an autologous graft should be preferred.
- A creeping substitution, i.e. a later improvement of the outcome up to one year post-operatively can often be observed.

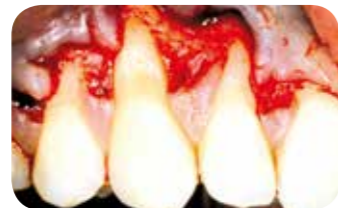CLINICAL CASE BY

Prof. Dr. Dr. Adrian Kasaj, University of Mainz, Germany

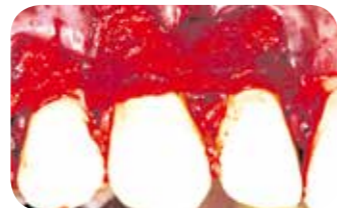RECESSION COVERAGE WITH THE MODIFIED CORONALLY ADVANCED FLAP TECHNIQUE¹³



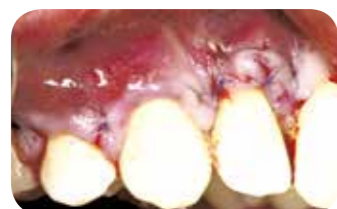Preparation of the exposed root surfaces by means of an air scaler and conditioning with 24% EDTA for two minutes



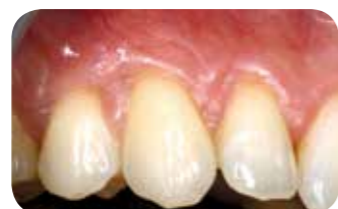A split-full-split flap preparation is performed according to Zucchelli and De Sanctis (2000)



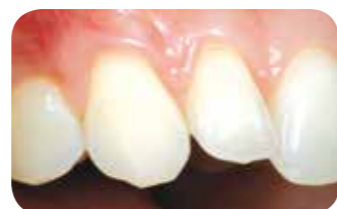mucoderm® is hydrated for ten minutes, trimmed, placed over the denuded root surfaces and sutured to periosteum with resorbable sutures



Coronal repositioning of the flap over root surfaces and matrix, and fixation with sling sutures



After three months: significant coverage of the root surfaces and increased tissue thickness



Clinical situation after 18 months



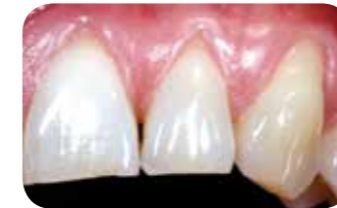Tips for using mucoderm® to treat gingival recessions

- Hydrate mucoderm® in blood or sterile saline for about ten minutes until its flexibility allows improved adaptation to the root surfaces.
- Immobilization of mucoderm® by suturing to the periosteum helps to avoid micromovements and ensures undisturbed revitalization, e.g. ingrowth of vessels and cells.
- Flap mobility should allow tension-free repositioning of the flap over mucoderm® and suturing (Check of the flap mobility: surgical papillae should rest passively on anatomical papillae).
- Pay attention to a complete coverage of the matrix.

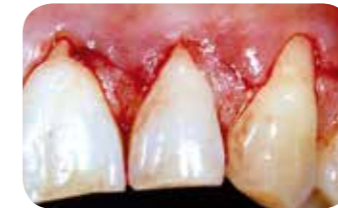CLINICAL CASE BY

Prof. Dr. Dr. Adrian Kasaj, University of Mainz, Germany

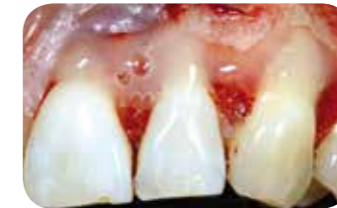RECESSION COVERAGE WITH THE MODIFIED CORONALLY ADVANCED FLAP TECHNIQUE IN COMBINATION WITH STRAUMANN® EMDOGAIN®¹¹



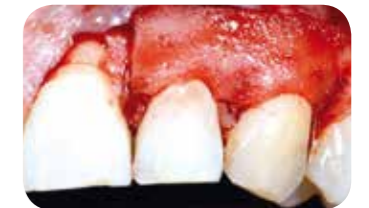Preoperative clinical situation, gingival recessions at teeth 21, 22, 23



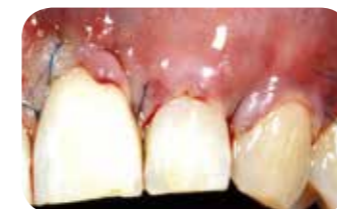Flap preparation by oblique incisions in the interdental soft tissues according to the modified coronally advanced flap technique (Zucchelli & De Sanctis 2000)



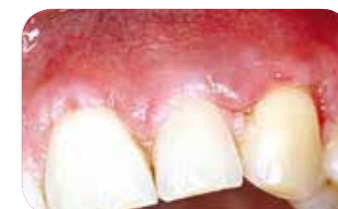Application of Straumann® Emdogain® on the clean and dry root surfaces



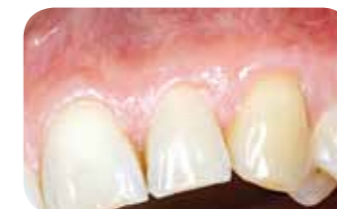mucoderm® is placed over the denuded root surfaces and tightly sutured to the periosteum



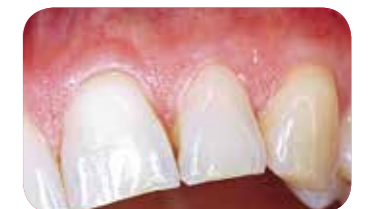Repositioning of the flap in coronal direction and fixation with sling sutures



Clinical situation four weeks post-operative



Clinical situation nine months post-operative



Clinical situation two years post-operative



Potential benefits of using mucoderm® in combination with Straumann® Emdogain® to treat gingival recessions

mucoderm® helps to maintain or increase gingival tissue thickness¹⁹, which may be of advantage in thin gingival biotype.

Adding Straumann® Emdogain® to a root coverage procedure with mucoderm®

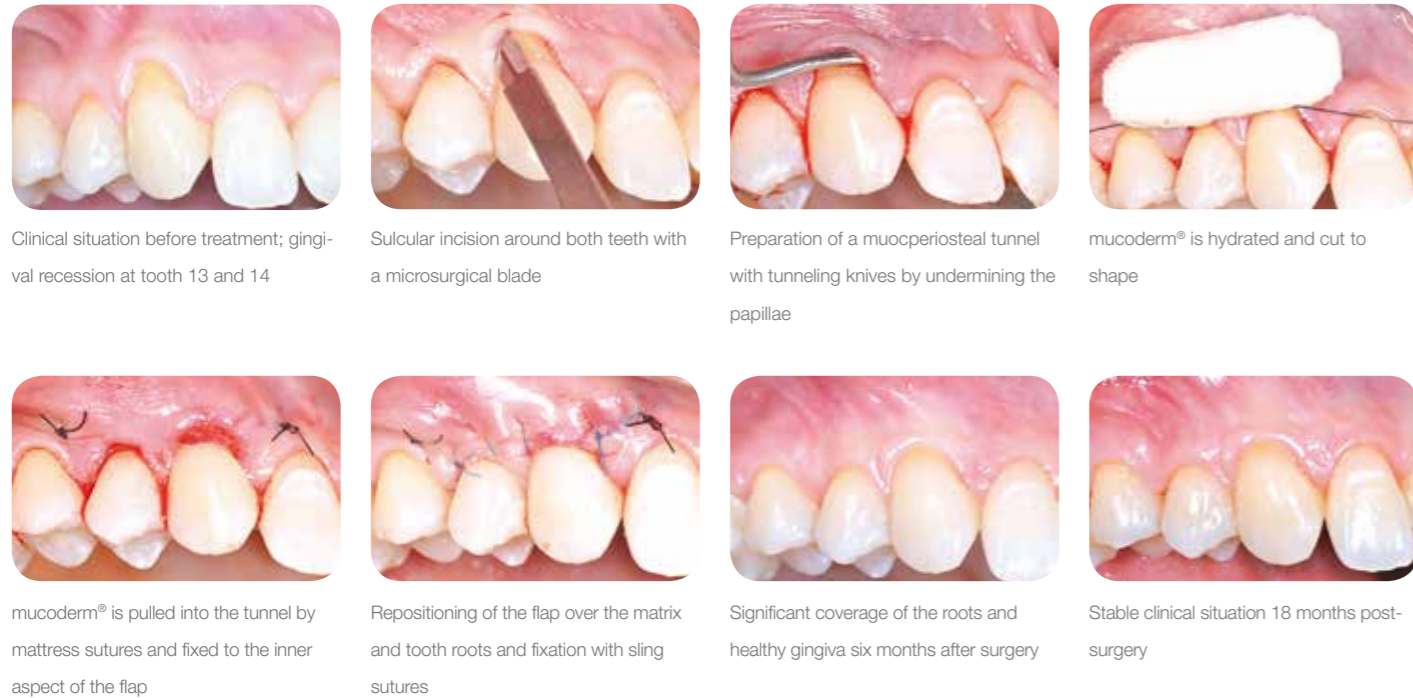- Improves the quality type of the attachment^{14,15}
- Stimulates angiogenesis^{16,17}, which may improve revascularization and integration of the mucoderm® collagen matrix
- Improves the quantity of keratinized tissue¹⁸, which may be beneficial in case of less or no residual keratinized gingiva

mucoderm® and Straumann® Emdogain® present a possible alternative to connective tissue graft for the treatment of multiple adjacent gingival recessions, when the modified coronally advanced tunnel technique is applied. These treatment modalities are associated with decreased patient chair time and decreased post-operative patient morbidity²⁰.

CLINICAL CASE BY

PD Dr. Raluca Cosgarea, University of Marburg, Germany

COVERING OF MULTIPLE RECESSIONS WITH THE MODIFIED CORONALLY ADVANCED TUNNEL (MCAT) TECHNIQUE



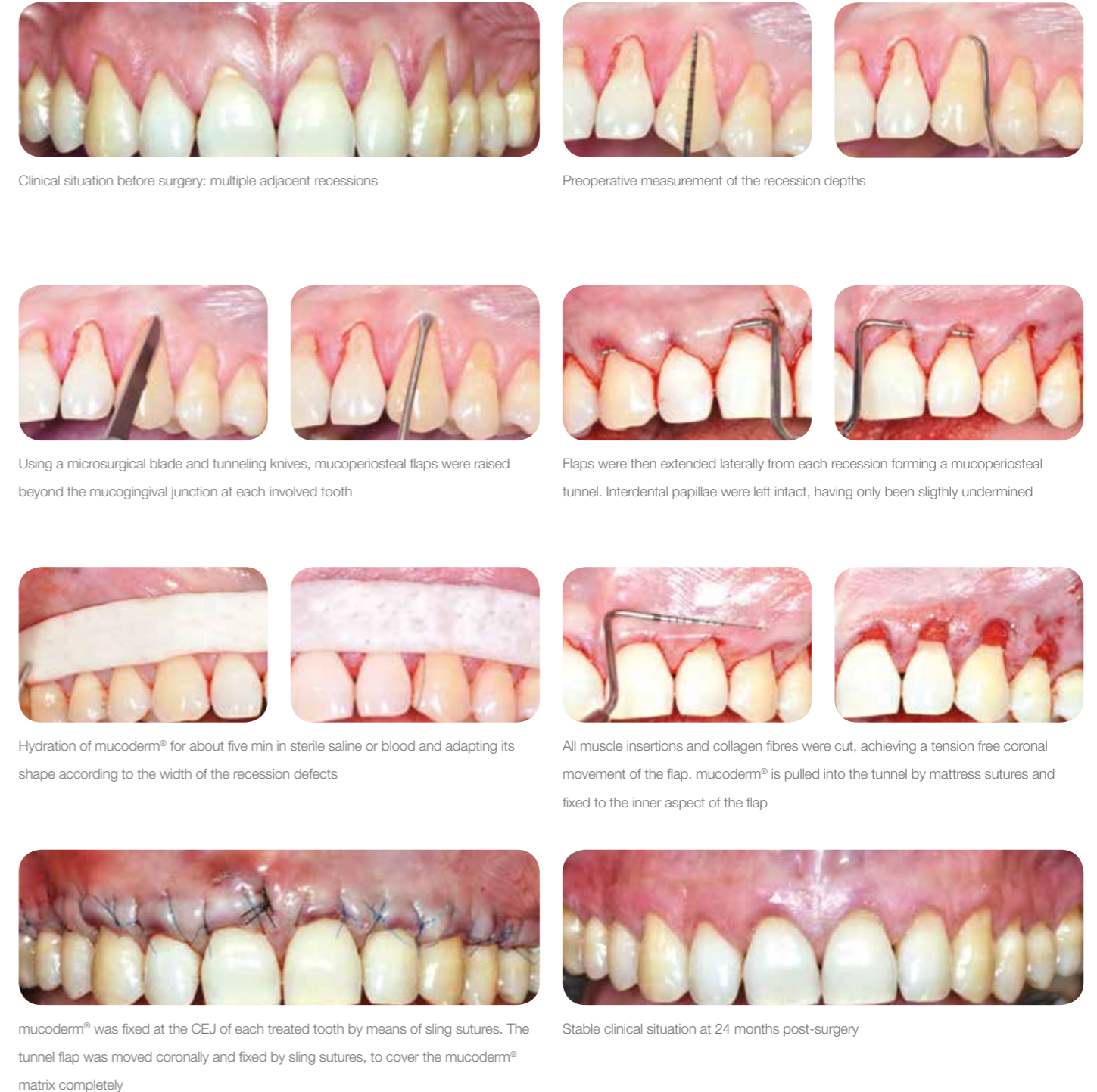Tips for using mucoderm to treat multiple recessions with tunneling techniques

- For the tunnel technique, a hydration of about ten minutes⁹ is recommended. This ensures a sufficient flexibility of the graft.
- Cutting all muscle insertions and inserting collagen fibres helps to achieve a tension-free coronal movement of the flap.
- In case of multiple adjacent recessions, mucoderm® can be pulled through the tunnel as described by Allen²¹.
- The matrix is pulled in the tunnel by means of mattress sutures and fixed at the inner aspect of the tunnel flap.
- To avoid movements of the matrix, mucoderm® can be fixed at the CEJ level of each treated tooth by means of sling sutures.

CLINICAL CASE BY

PD Dr. Raluca Cosgarea, University of Marburg, Germany and Prof. Dr. Dr. Anton Sculean, University of Bern, Switzerland

COVERING OF MULTIPLE RECESSIONS WITH THE MODIFIED CORONALLY ADVANCED TUNNEL (MCAT) TECHNIQUE¹⁰

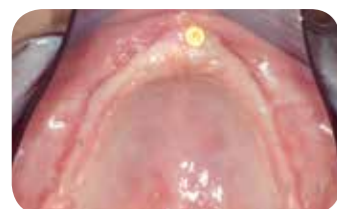

CLINICAL CASE BY

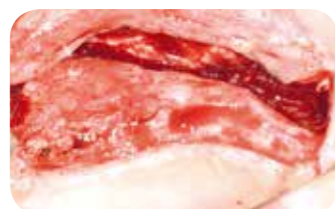
Dr. Bálint Molnár and Prof. Dr. Péter Windisch, University of Budapest, Hungary

FULL ARCH RECONSTRUCTION OF INSUFFICIENT VESTIBULAR DEPTH AND LACK OF KERATINIZED TISSUES

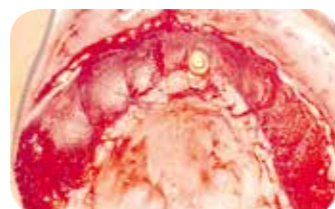
APPLICATION OF MUCODERM® WITH AN APICALLY REPOSITIONED SPLIT THICKNESS FLAP DESIGN.



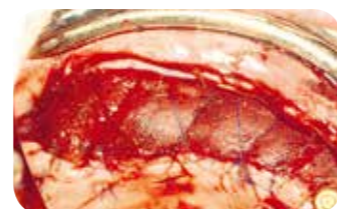
Insufficient keratinized mucosa and extremely shallow vestibulum on the edentulous maxilla following bilateral sinus floor elevation and horizontal GBR therapy of knife edge ridges



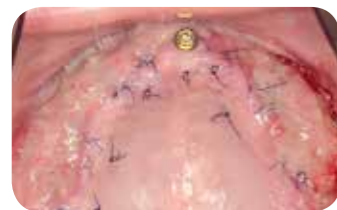Apically repositioned flap by palatal incision along the maxilla. Split-thickness flap preparation with an intact periosteal layer over the augmented bone



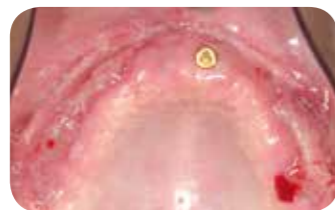Fixation of the buccal flap to the exposed periosteum deep in the vestibular fold. Fixation of mucoderm® with resorbable monofilament (Monolac) single and cross-typed sutures



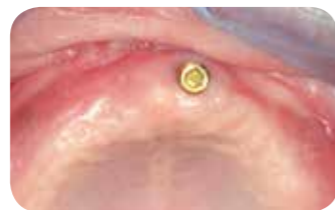mucoderm® fixed to the periosteum with single and cross-sutures



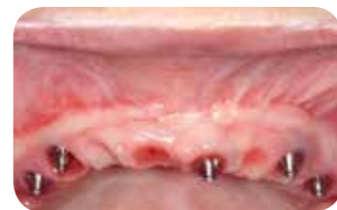Clinical situation after one week: secondary epithelization and newly formed capillary vessels detectable



Clinical situation after two weeks: secondary healing continued over mucoderm® treated areas, remaining sutures were removed



Clinical situation after four weeks: secondary healing completed



Clinical situation after six months: excellent tissue maturation, favourable color and thickness of the newly formed soft tissue around the implants



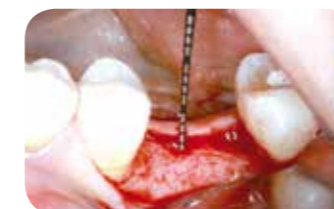Tips for using mucoderm® to augment the attached gingiva

- A band of at least 1 mm of keratinized gingiva should be present to provide the biological information needed for regeneration of the grafted site.
- Prior to application, mucoderm® should be hydrated in sterile saline or blood for about five minutes.
- A close contact between mucoderm® and the wound bed is required for the revitalization of the graft. Close adaptation may be achieved by pressing the matrix to the wound bed for several seconds.
- Deep periosteal sling sutures and superficial mattress or single interrupted sutures may be applied to immobilize the graft and achieve tight contact to the underlying periosteum.
- If possible, mucoderm® should be sutured tension-free to the surrounding soft tissue. A sufficient depth of the vestibule is necessary for a tension-free suturing of the apical aspect of mucoderm®.
- mucoderm® can be left exposed for open healing without any wound dressing^{23,24,25} as described on page 5.
- A shrinkage of the augmented tissue might be observed even after several months. Long-term follow-up studies are currently being performed to quantify the degree of shrinkage and tissue stability for this particular indication.
- mucoderm® may also be applied to correct scars and create fixed gingiva in case of lip or cheek frenulum section. Complete immobilization of mucoderm® is of utmost importance in these indications.

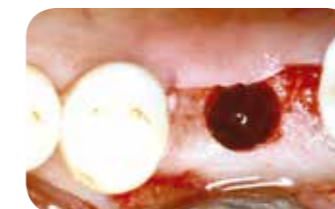
CLINICAL CASE BY

Dr. Algirdas Puisys, Privat Clinic, Lithuania

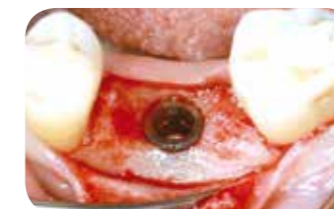MUCODERM® FOR THE THICKENING OF PERIIMPLANT SOFT TISSUE MUCOSAL THICKENING AROUND BONE LEVEL IMPLANTS²⁶



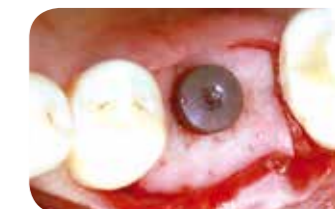Incision in the center of the edentulous ridge and raising a full-thickness flap buccally and lingually



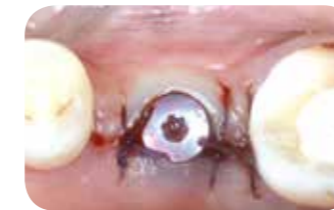Bone preparation for Straumann® Bone Level implant placement



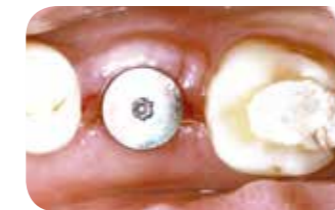Implant insertion and contouring crestal bone with a straight handpiece



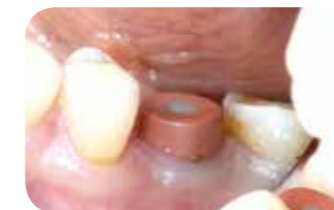Hydrated mucoderm® perforated and pulled over the healing cap



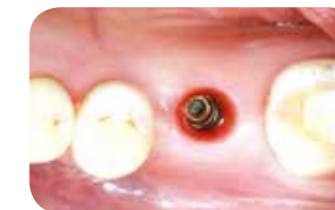The margins of the flap are adapted and sutured leaving the abutment open



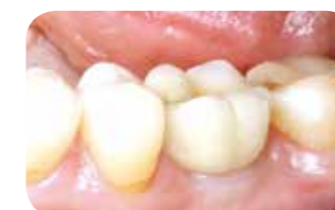Situation after one week and after suture removal



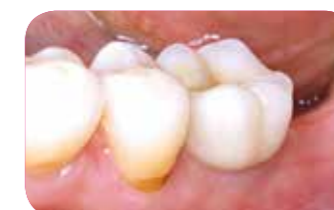Wider healing abutment after four months



Smooth emergence profile visible after the removal of the healing abutment



Final restoration after five months



Stable clinical situation after five years



Tips for using mucoderm® to thicken the periimplant soft tissue

- Thickening of the mucosa can be performed prior to implantation or with simultaneous implant placement. In both cases a mucoperiosteal flap can be prepared and mucoderm® can be placed with direct contact to the bone.
- Prior to application, mucoderm® must be hydrated in sterile saline or blood for ~ten minutes to ensure a sufficient flexibility of the graft.
- After hydration, mucoderm® can easily be perforated.
- mucoderm® can be placed in direct contact with the bone.
- mucoderm® should extend mesiodistally to the neighbouring teeth, buccally ~10 mm and lingually ~5 mm beyond the implant margin.
- mucoderm® should be covered by the flap to ensure revitalization of the matrix. If only minor parts of the matrix are exposed, revascularization can occur from the surrounding margins of the flap.

FEATURES AND BENEFITS of mucoderm®

- mucoderm® is a three-dimensional collagen matrix that supports fast vascularization and soft tissue integration.
- mucoderm® remodels completely into newly formed tissue within approx. six to nine months, providing a valuable alternative to the patient's own tissue in certain indications.
- Its high tensile strength allows mucoderm® to be shaped and used for any surgical soft tissue techniques (including the tunnel technique).

mucoderm® provides a suitable alternative in specific indications to the patient's own connective tissue.

Further advantages of mucoderm® are²⁴:

- Reduced patient chair time
- Reduced surgical and post-surgical bleeding
- No need for donor tissue harvesting (i.e., no donor site morbidity/pain, faster recovery from surgical intervention)
- Good integration into surrounding tissue with respect to color and texture

Product Specifications

mucoderm® has a thickness between 1.2-1.7 mm

| Art.-No. | Dimensions | Content |
|----------|------------|------------|
| 701520 | 15 × 20 mm | 1 × matrix |
| 702030 | 20 × 30 mm | 1 × matrix |
| 703040 | 30 × 40 mm | 1 × matrix |



References

- 1: Studor SP, Allen EP, Rees TC, Kouba A. The thickness of masticatory mucosa in the human hard palate and tuberosity as potential donor sites for ridge augmentation procedures. J Periodontol. 1997;68(2):145-151.
- 2: Monnet-Corti V, Santini A, Gilse JM, et al. Connective tissue graft for gingival recession treatment: assessment of the maximum graft dimensions at the palatal vault as a donor site. J Periodontol. 2006;77(5):899-902.
- 3: Wessel JR, Tatakis DN. Patient outcomes following subepithelial connective tissue graft and free gingival graft procedures. J Periodontol. 2008 Mar;79(3):425-30.
- 4: Griffin TJ, Cheung WS, Zavras AI, Damoulis PD. Postoperative complications following gingival augmentation procedures. J Periodontol. 2006 Dec;77(12):2070-9.
- 5: Ramachandra SS, Rana R, Reetika S, Jithendra KD. Options to avoid the surgical site: a review of literature. Cell Tissue Bank 2014, 15(3): 297-305.
- 6: Pabst AM, Happe A, Callaway A, Ziebart T, Stratul SI, Ackermann M, Konerding MA, Willershausen B, Kasaj A. In vitro and in vivo characterization of porcine acellular dermal matrix for gingival augmentation procedures. J Periodont Res. 2014, 49(3): 37-81
- 7: Rothamel D, Benner M, Fienitz T, Happe A, Kreppel M, Nickenig HJ and Zöller JE Biodegradation pattern and tissue integration of native and cross-linked porcine collagen soft tissue augmentation matrices – an experimental study in the rat. Head and Face 2014, 10:10.
- 8: Pabst AM, Wagner W, Kasaj A, Gebhardt S, Ackermann M, Astolfo A, Marone F, Haberthür D, Enzmann F, Konerding M A. Synchrotron-based X-ray tomographic microscopy for visualization of three-dimensional collagen matrices. Clin Oral Investig 2015, 19(2):561-4.
- 9: Kasaj A, Levin L, Stratul SI, Götz H, Schlee M, Rütters CB, Konerding MA, Ackermann M, Willershausen B, Pabst AM. The influence of various rehydration protocols on biomechanical properties of different acellular tissue matrices. Clin Oral Invest. 2015.
- 10: Cosgarea R, Juncar R, Lascu L, Arweiler N, Sculean A. Treatment of multiple gingival recession defects with a new collagen membrane. Poster Europerio London 3-6 June 2015. Manuscript submitted.
- 11: Vincent-Bugnas S, Borie G, Charbit Y. Treatment of multiple maxillary adjacent class I and II gingival recessions with modified coronally advanced tunnel and a new xenogeneic acellular dermal matrix. J Esthet Restor Dent. 2018 Mar;30(2):89-95.
- 12: Mörmann W, Ciancio SG. Blood supply of human gingiva following periodontal surgery. A fluorescein angiographic study. J Periodontol. 1977 Nov;48(11):681-92.
- 13: Kasaj A. Treatment of multiple recessions with a modified coronally advanced flap. International Dentistry African Edition 2014. 5(1): 50-51
- 14: McGuire MK, Cochran DL. Evaluation of human recession defects treated with coronally advanced flaps and either enamel matrix derivative or connective tissue. Part 2: Histological evaluation. J Periodontol. 2003 Aug;74(8):1126-35.
- 15: Shirakata Y, Sculean A, Shinohara Y, Sena K, Takeuchi N, Bosshardt DD, Noguchi K. Healing of localized gingival recessions treated with a coronally advanced flap alone or combined with an enamel matrix derivative and a porcine acellular dermal matrix: a preclinical study. Clin Oral Investig. 2015 Nov 27.
- 16: Kasaj A, Meister J, Lehmann K, Stratul SI, Schlee M, Stein JM, Willershausen B, Schmidt M. The influence of enamel matrix derivative on the angiogenic activity of primary endothelial cells. J Periodontol Res. 2012 Aug;47(4):479-87.
- 17: Aspriello SD, Zizzi A, Spazzafumo L, Rubini C, Lorenzi T, Marzoni D, Bullon P, Piemontese M. Effects of enamel matrix derivative on vascular endothelial growth factor expression and microvessel density in gingival tissues of periodontal pocket: a comparative study. J Periodontol. 2011 Apr;82(4):606-12.
- 18: Pilloni A, Paolantonio M, Camargo PM. Root coverage with a coronally positioned flap used in combination with enamel matrix derivative: 18-month clinical evaluation. J Periodontol. 2006 Dec;77(12):2031-9.
- 19: Al-Hezaimi K, Al-Fahad H, O'Neill R, Shuman L, Griffin T. The effect of enamel matrix protein on gingival tissue thickness in vivo. Odontology. 2012 Jan;100(1):61-6.
- 20: Miinkovic I, Rakasevic D, Aleksic Z, Jankovic S. Clinical application of collagen tissue matrix and enamel matrix derivative in the treatment of multiple gingival recessions. A randomized controlled clinical trial. Poster Europerio London 2015.
- 21: Cieslik-Wegemund M, Wierucka-Mlynarczyk B, Tanasiewicz M, and Gilowski Ł. Collagen Matrix With Tunnel Technique Compared to Connective Tissue Graft for the Treatment of Periodontal Recession – Randomized Clinical Trial. Journal of Periodontology, Ahead of print. July 17, 2016. (doi:10.1902/jpp.2016.150676)
- 22: Allen AL. Use of suprapariosteal envelope in soft tissue grafting for root coverage. I. Rationale and technique. Int J Periodontics Restorative Dent. 1994; 14(3):216-27.
- 23: Konstantinova D, Djongova E, Arnautska H, Georgiev T, Peev S, Dimova M. Presentation of a modified method of vestibuloplasty with an early prosthetic loading. J of IMAB. 2015 Oct-Dec;21(4):964-968.
- 24: Nocini PF, Castellani R, Zanotti G, Gelpi F, Covani U, Marconicini S, de Santis D. Extensive keratinized tissue augmentation during implant rehabilitation after Le Fort I osteotomy: using a new porcine collagen membrane. J Craniofac Surg. 2014, May;25(3):799-803
- 25: Stricker A, Rothamel D, Stübinger S, Fleiner F. Evaluation of a porcine matrix to create new keratinized tissue at deficient implant sites: 12 months results from a controlled prospective clinical study. Poster EAO Rome 2014.
- 26: Puisys A, Schlee M, Vindasiute E, Linkevicius T. Vertical soft tissue augmentation with porcine-derived collagen matrix membrane: A prospective study with 20 consecutive patients. EAO Stockholm 2015. Manuscript in preparation.

bone & tissue
regeneration

botiss
biomaterials

Innovation.
Regeneration.
Aesthetics.

soft tissue

education

hard tissue

botiss biomaterials GmbH
Hauptstr. 28
15806 Zossen
Germany

Tel.: +49 33769 / 88 41 985
Fax: +49 33769 / 88 41 986

www.botiss.com
www.botiss-dental.com
facebook: botissdental