bone & tissue regeneration

botiss biomaterials

SURGICAL GUIDE

according to Dr. Jochen Tunkel

maxgraft® cortico

SHELL TECHNIQUE WITH ALLOGENIC CORTICAL PLATES

innovative

efficient

atraumatic

hard tissue

Dr. Jochen **Tunkel**

"The question which augmentative procedure can be called the gold standard **has changed in recent years and will have to change further.** The combination of the shell technique with maxgraft® cortico and consecutive augmentative relining with cerabone® and Jason® membrane enables me to augment predictably and with reduced invasiveness even in cases of pronounced bone defects, without having to compromise on the results of the gold standard autogenous bone. **This represents a sustainable gain for my daily practice.**"

Fachzahnarzt (German Postgraduate Degree) in periodontology

Fachzahnarzt (German Postgraduate Degree) in oral surgery

Master of oral medicine in implantology

Specialist of the German Society of Periodontology (DGParo)

2020 Founding of the online social media learning platform "Regenerative Bioversity"

2020 Private practice announced as maxgraft® cortico Competence Center

2019 Announcement as ITI speaker

2018 Announcement as ITI Fellow

2004-2015 Assistant Professor, Department of Periodontology, University Clinic Münster, Germany

since 2008 Chairman of the section „surgical periodontology" of the German society of oral surgery

since 2007 Private referral practice for implantology, periodontology and oral surgery in Bad Oeynhausen, Germany

2007 Fachzahnarzt (German postgraduate degree) in oral surgery

2006 Master of oral medicine in implantology

2004-2006 3-year postgraduate program in oral surgery at the dental clinic "Schloß Schellenstein" (chairman Prof. Dr. Fouad Khoury)

2003 Specialist of the German Society of Periodontology (DGParo)

2003 Fachzahnarzt (German postgraduate degree) in periodontology

2000-2003 3-year postgraduate program in periodontology at the Department of Periodontology, University Clinic Münster, Germany (chairman Prof. Dr. Thomas Flemmig)

Preoperative assessment and precautions

Key elements for an optimal surgical procedure and long-term treatment success include:
- Careful patient selection in terms of health status, compliance and patient's dental status
- Consideration of patient-related factors that may affect bone healing (e.g., diabetes, smoking)
- Consideration of the soft tissue, preoperative soft tissue management may be required
- Treatment of any inflammation and infection prior to surgery (especially the periodontal conditions should be perfectly treated to reach an inflammation-free status)
- Antibiotic treatment starting prior to surgery and to be continued for 7-10 days
- Postoperative rinsing with chlorhexidin solution is recommended
- Comprehensive patient information about the treatment plan and origin of the bone substitute materials

Courses or hands-on workshops should be attended prior to initial use. Preferably, the surgeon should be experienced in harvesting autogenous bone grafts. The difficulty of the shell technique increases with the size of the defect, when the contact with the local bone is reduced, or when a second cortical plate is fixed on the opposite side of the ridge.

Use of maxgraft® cortico in conjunction with other biomaterials

maxgraft® cortico is a thin, stable cortical plate made from human donor bone, specifically designed for the shell technique. The shell technique creates a stable biological container that can be filled with particulate bone substitute material, facilitating revascularization and migration of bone-forming cells into the defect zone for rapid bone regeneration[1]. Mixing autogenous bone chips with maxgraft® granules is recommended[2]. The collagen contained in maxgraft® granules enables very good osteoconduction and complete remodeling of the particles[3]. Additional relining of the augmented side with cerabone®, a volume-stable bovine bone substitute, immediately after implant placement may prevent early resorption and increase the bone volume gained by up to 17%[1,4]. The augmentation side then needs to be covered with a barrier membrane e.g., Jason® membrane to prevent soft tissue ingrowth into the particulate material.

References

1. Tunkel et al. Clin Case Rep. 2020;9(2):947-959.
2. Kämmerer et al. Int J Implant Dent. 2022. 1;8(1):48.
3. Trajkovski et al. Materials 2018, 11(2).
4. De Stavola & Tunkel. Int J Oral Maxillofac Implants. 2013;28(4):1062–7.
5. Pabst et al. J Investig Surg, 2020, 1158-1164.

Surgical procedure

Step 1 **FLAP PREPARATION**

A flap large enough to allow full access to the entire defect should be elevated. Adequate revascularization of the particulate bone grafting material is also critical and needs to be ensured. The required size and position of the bone plate can be determined either during the digital planning of the surgery or in situ after flap elevation.

Step 2 **TRIMMING**

maxgraft® cortico cannot be bent to follow the contour of the alveolar ridge. The plate is completely mineralized cortical bone and is not flexible. When used in the anterior region or in extremely curved alveolar ridges, the cortical plate can be divided and fixed in multiple pieces. By using the cortico trimmer and a rotating diamond disk, maxgraft® cortico is cut extraorally to the appropriate size. Shaping is essential, see page 8.

Note: Rehydration of maxgraft® cortico is recommended. It has been shown that rehydration of maxgraft® cortico (10 minutes in saline solution) results in increased flexibility and improved fracture resistance of the cortical plate[5].

Step 3 **PLACEMENT AND FIXATION**

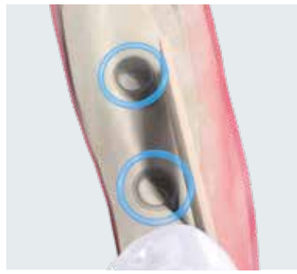

In order to create a fixed compartment, maxgraft® cortico must be placed at the appropriate distance but still in contact with the local bone. Based on the ideal implant position, the cortical plate should be positioned with at least a 1 mm distance from the implant surface when placed laterally. Tension-free fixation without bending of the cortical plate is highly important.

Note: Augmentation outside the alveolar ridge contour should be avoided, as this may lead to either non-integration of the plate or even worse dehiscence[2].

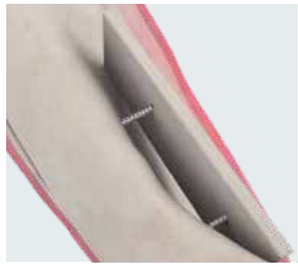

Note - screws: Predrilling is mandatory to reduce the risk of plate fracture[2]. The drill head must be smaller than the diameter of the screw (e.g., 0.8 mm drill with a 1.0 mm screw) in order to maintain the stability of the cortical plate. It is recommended to use osteosynthesis screws with a flat head. Screws with a conical shaped head have to be avoided absolutely. Screws with a diameter of 1.0 - 1.2 mm and a length of 6 to 14 mm are suitable for most defects. Self-tapping screws should be avoided as they may result in fracture of the bone plate due to the aggressive thread design. Sinking the screw head into the bone plate should also be avoided, as this may result in a loss of stability and weakens the plate leading to higher risks of fractures.

Step 4 **ADAPTATION OF THE EDGES**

To avoid soft tissue perforation, sharp edges needs to be removed, e.g. with a diamond bur. Smoothening of the sharp edges should usually be done outside the mouth but can of course also be finished after fixing the plates.

Step 5 **FILLING OF THE DEFECT**

The space between the local bone and the cortical plate is filled with particulate bone grafting materials. The use of either pure autologous particles or a layered filling of the defect with allogeneic chips (e.g. maxgraft®) covered by pure autologous bone chips is recommended[2].

Step 6 **COVERAGE BY A BARRIER MEMBRANE**

Just in the case that only allogeneic chips have been used for defect filling the augmentation side needs to be covered by a membrane (e.g., Jason® membrane). The barrier membrane prevents soft tissue from growing into the particulate material.

Step 7 **WOUND CLOSURE**

The suture has to be tension-free and saliva-proof. Proper soft tissue management is critical to the surgical success. Tension-free wound closure and adequate soft tissue quality significantly reduce the risk of complications such as dehiscence. Overlapping soft tissue mobilization should be possible prior to suturing.

Tension-free suture technique

Single interrupted sutures alternating with horizontal mattress sutures should be used for primary closure. Deep apical sutures with elastic Gore-Tex® threads can be used to immobilize the flaps, eliminating any tension at the wound edges that could lead to dehiscence.

POST-OPERATIVE CARE

- Postoperative CBCT or X-ray should be considered.
- Postoperative X-ray is mandatory to control appropriate placement of screws.
- A thorough analgesics protocol should be followed directly after surgery.
- Chlorhexidine rinse 3 times daily should be prescribed until suture removal.
- Usually an antibiotic prophylaxis should be continued for 3-10 days.
- Sutures should be removed after 14 days.
- Arrange follow-up visits in 4-6 weeks intervalls to control early wound-healing problems.

HEALING, REMODELING, AND INTEGRATION

Postoperatively, maxgraft® cortico usually gets primarily integrated. Since the bone plate consists of cortical bone, it acts as a resorption protection and is gradually remodeled. Resorption occurs primarily in areas outside the contour. New vital bone is formed directly adjacent to the allogenic plate on the side facing the local bone. In comparison to autogenous grafts, maxgraft® cortico demonstrates long-term stability.

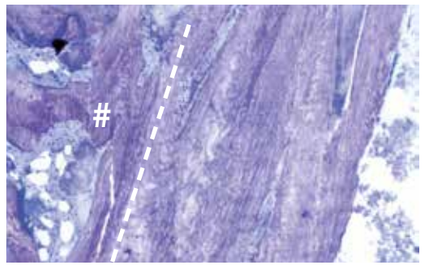

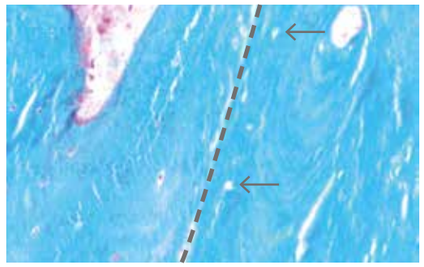

The histological images show an integrated maxgraft® cortico bone plate (right side of dashed line) with allogeneic particles (#) stabilized in the container after five months of healing time. maxgraft® cortico is characterized by empty osteocyte lacunae (arrows), whereas the newly generated bone shows a large number of vital osteocytes.

Biopsy provided by Jan Kielhorn (Öhringen, Germany) processed by Prof. Smeets (UKE Hamburg, Germany).

RE-ENTRY AND IMPLANT PLACEMENT

Depending on the location, type, and extent of the defect, the entire healing time is four to six months when using a mixture of allogenic and autogenous bone particles. However, the right time for the re-entry needs to be assessed individually by the surgeon. After flap preparation usually a slight smoothening of the plates is necessary before placing the implants.

The implant has to be securely anchored in the cancellous bone and should not be in contact with the plate.

AUGMENTATIVE RELINING AFTER IMPLANTATION

The additional use of augmentative relining is recommended. The additional layer of xenogenic bone substitute material (e.g. cerabone®) and a collagen membrane (e.g. Jason® membrane), aims to prevent bone resorption in the period between implantation and prosthetic restoration, especially in the first 24 months after augmentation, during which the bone undergoes continuous remodelling[1,4].

THE SHAPES OF THE BONE SHELLS

by Dr. Jochen Tunkel

Well-fitting shells are almost never rectangular, therefore it needs defect-dependent shapes for every case.

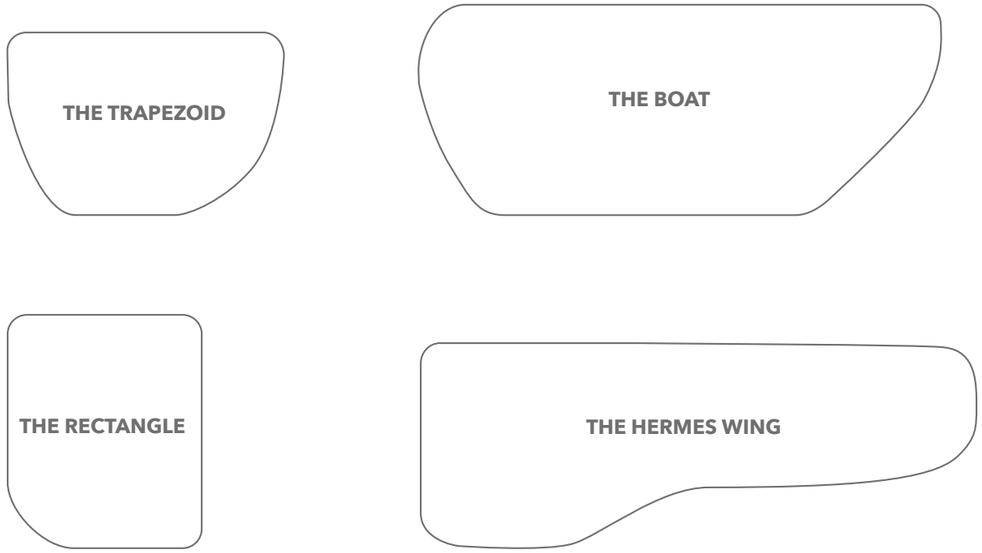

THE TRAPEZOID Mostly used on buccal and oral sites, in anterior as well as in posterior areas especially in single tooth gaps.

THE RECTANGLE Mostly used on buccal sites in the aesthetic area and also in huge augmentations in highly curved defects.

THE BOAT Mostly used on palatal and lingual sites, but also buccally in the upper jaw.

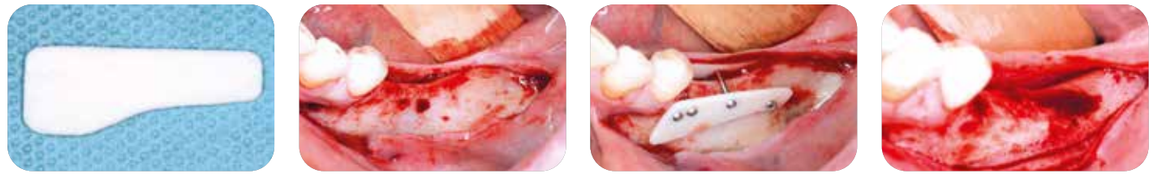

THE HERMES WING Mostly used on buccal sites, especially in the posterior area due to the external oblique line or the lateral wall of the sinus.

Complication management

Fracture of the bone plate

maxgraft® cortico is a highly stable bone plate. It must be fixed without any movement and without excessive pressure or tension. In the unlikely event of a fracture, it must be fixated with an additional screw or replaced by a new bone plate. Additionally the use of the cortico trimmer reduces the risk of a fracture during cutting and is ideal for precise adaptation.

Wound dehiscence

maxgraft® cortico is acellular; even exposed maxgraft® cortico is resistant to bacterial degradation. In absence of any signs of infection optimize oral hygiene in combination with mouth rinsing solutions (0.2% chlorhexidine), up to three times a day[2].
Avoid removing the cortical plate in cases without a putrid infection or pain or other compelling reasons. Smoothen sharp edges or reduce free-standing parts of the cortical plate below tissue level if possible.

Soft tissue perforations

Late soft tissue perforations after normal wound healing: In absence of any signs of infection, reduce sharp edges or remove free-standing parts of the bone plate. Avoid removing the cortical plate in cases without a putrid infection or pain or other compelling reasons. In the case of irritations of surrounding soft tissue, use rinsing protocol as described above.

Detached maxgraft® cortico at the time of re-entry

In rare cases, it can occur that the plate is not connected to the bony site and must therefore be removed. The augmentation site is usually fully regenerated. Usually detachment of the plate is a complication when placed outside of the contour.

CLINICAL CASE BY
Dr. Jochen Tunkel

SINGLE TOOTH RESTORATION


Pre-operative situation


Clinical situation


Adaptation of maxgraft® cortico and fixation buccally and lingually with 1 mm micro-screws


Filling and contouring of the defect with autogenous chips


Saliva-tight and tension-free wound closure


Part of postoperative panoramic X-ray


Solid integration of maxgraft® cortico and implant placement


Relining technique with cerabone® plus


Covering of the augmentation site with Jason® membrane


Complication-free soft tissue healing


Kazanjian vestibuloplasty

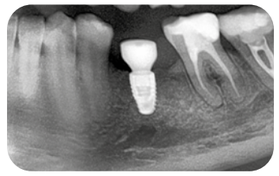
Final X-Ray

CLINICAL CASE BY
Dr. Jochen Tunkel

FREE END SADDLE IN THE MANDIBLE


Clinical situation


Adaptation of maxgraft® cortico and fixation buccally and lingually with 1 mm micro-screws


Filling and contouring of the defect with autologous and allogeneic chips in a layered approach

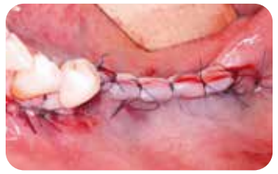
Saliva-tight and tension-free wound closure


Solid bone formation and integration of maxgraft® cortico


Implant placement 4 month after augmentation


Relining technique with cerabone®


Covering of the augmentation site with Jason® membrane


Saliva-tight and tension-free wound closure


Uneventful soft tissue healing 4 months after implantation


Re-entry with stab incision combined with Kazanjian vestibuloplasty


Final dental crowns

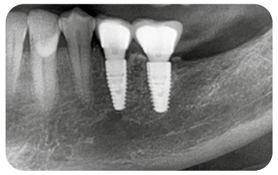
Final X-Ray

CLINICAL CASE BY
Dr. Jochen Tunkel

RIDGE AUGMENTATION IN THE MAXILLA AND SIMULTANEOUS SINUS LIFT


Clinical situation pre-operative


Mobilization of the Schneiderian membrane and adaptation of maxgraft® cortico and fixation buccally and lingually with 1 mm micro-screws


Filling and contouring of the defect with autologous and allogeneic chips in a layered approach and closure of the lateral window with permamem®


Saliva-tight and tension-free wound closure

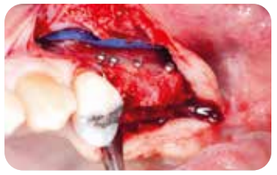
Solid bone formation and integration of maxgraft® cortico and removal of permamem®


Implant placement 4 months after augmentation

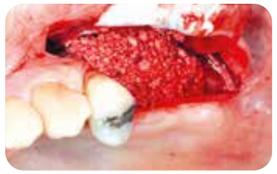
Relining technique with cerabone®


Covering of the augmentation site with Jason® membrane


Saliva-tight and tension-free wound closure


Uneventful soft tissue healing 4 months after augmentation


Reentry using an apically repositioned flap

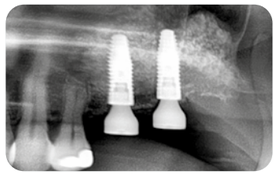
Final X-Ray


Final dental crowns

CLINICAL CASE BY
Dr. Jochen Tunkel

FREE END SADDLE IN THE MANDIBLE

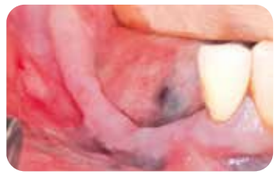
Highly atrophic situation in the mandible

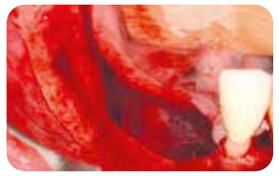
Bone defect at opening


Adaption of autogenous and allogenic cortical plates and fixation buccally and lingually with 1 mm microscrews

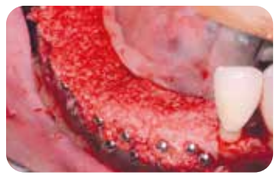
Filling of the defect with maxgraft® granules with autogenous chips on top

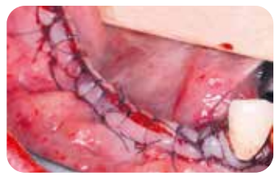
Suturing with alternating mattress and single interrupted sutures after thorough flap mobilization

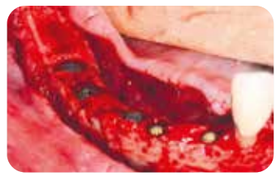
Solid bone formation and integration of maxgraft® cortico and Implant placement
4 months after augmentation


Relining technique with cerabone®


Covering of the augmentation site with Jason® membrane


Kazanjian vestibuloplasty


Final dental crowns


Final X-Ray

NOTES

bone & tissue regeneration

botiss biomaterials

Innovation.
Regeneration.
Aesthetics.

hard tissue

education

soft tissue

botiss biomaterials GmbH
Hauptstr. 28
15806 Zossen
Germany

Tel.: +49 33769 / 88 41 985
Fax: +49 33769 / 88 41 986

www.botiss.com
facebook: botissdental
instagram: botiss_dental

Rev.: SGMGCOen-01/2023-07_Jochen Tunkel